



Case Report: Excessive Blood Glucose in Diabetic Ketoacidosis and Hyperosmolar Hyperglycemia: A Rare Case Report

Alireza Kashanizadeh

Department of Internal Medicine, School of Medicine, Ganjavian Hospital, Dezful University of Medical Sciences, Dezful, Iran

Ahmad Reza Salmanpour

Department of Internal Medicine, School of Medicine, Ganjavian Hospital, Dezful University of Medical Sciences, Dezful, Iran

Nasim Shirin Sahrae

Department of Internal Medicine, School of Medicine, Ganjavian Hospital, Dezful University of Medical Sciences, Dezful, Iran

Mohammad Firoozbakht

Student Research Committee, Dezful University of Medical Sciences, Dezful, Iran

Hamid Karimi

Department of Internal Medicine, School of Medicine, Ganjavian Hospital, Dezful University of Medical Sciences, Dezful, Iran

ARTICLE INFO

Submitted: 17 Sep 2021
Accepted: 04 Nov 2021
Published: 01 Dec 2021

Keywords:

**Diabetic ketoacidosis;
Hyperosmolar hyperglycemic
state;
Type 1 diabetes**

Correspondence:

Hamid Karimi, Department of Internal Medicine, School of Medicine, Ganjavian Hospital, Dezful University of Medical Sciences, Dezful, Iran.

Email:

Hamidkarimi0641@gmail.com

ORCID: 0000-0001-5863-7387

Citation:

Kashanizadeh A, Salmanpour AR, Shirin Sahrae N, Firoozbakht M, Karimi H. Evaluation of Patients' Anxiety about COVID-19 Infection through Dental Visits in Sari Dental School Clinic in 2021. *Tabari Biomed Stu Res J.* 2021;3(4):52-56.

 [10.18502/tbsrj.v3i4.7797](https://doi.org/10.18502/tbsrj.v3i4.7797)

ABSTRACT

Type 1 diabetes (T1D) is an autoimmune assault on pancreatic β -cells characterized by a decrease in insulin production. The worldwide incidence rate of T1D is reportedly increasing. In parallel with the increase of T1D, diabetic ketoacidosis (DKA) and hyperosmolar hyperglycemic state (HHS) also appear as two risk factors for hyperglycemia. This case report presents a T1D patient with DKA and HHS who was finally discharged after recovery.

Introduction

Type 1 diabetes (T1D) refers to the destruction of insulin-producing pancreatic beta cells during auto-immune process, which is characterized by a reduction in insulin synthesis. The incidence rate of the T1D is increasing throughout the world reportedly (1, 2). This rate has been

reported to vary widely in many countries, with the highest rates in Finland and the lowest rates in Asia (3).

Increased risk of T1D has led to the emergence of diabetic ketoacidosis (DKA) and hyperosmolar hyperglycemic state (HHS) as two risk factors for hyperglycemia

(4). According to studies, the incidence of DKA with T1D depends on the geographical area, so that this rate varies from 15 to 67% (5).

Based on the findings, most cases of HHS are observed in elderly patients with type 2 diabetes (T2D), and HHS is very rare as the first clinical manifestation of T1D (6, 7). Because of the similar characteristics and manifestations of these two disorders, it is not easy to diagnose DKA and HHS in the patient. However, there are criteria provided for their diagnosis. The HHS appears as severe hyperglycemia, with excessive osmolality and no evidence of severe ketosis or acidosis. Although the HHS is a rare clinical manifestation of T1D, its importance cannot be ignored due to high mortality rate, especially in children(8). The present case report introduces the T1D patient with DKA and HHS.

Case Presentation

The patient is a 22-year-old woman who was referred to the hospital in a state of decreased consciousness. The patient had a history of weakness and lethargy for about a month, which worsened three or four days before the visit, and she also had a great thirst for a month, consuming a lot of water. The patient's urine output was also elevated. She did not complain of feeling hungry or eager to eat, and only complained of anorexia for three or four days. She has not lost much weight. According to her caregiver, the patient did not complain of abdominal pain and nausea before referring and reducing the level of consciousness and did not vomit. The patient's breathing was not fast, deep and abnormal. Prior to or during the onset of this state of weakness and lethargy, the patient had not experienced specific conditions such as colds and symptoms including cough, dyspnea, diarrhea and food poisoning, fever, body aches, and vaginal discharge. Only the patient's mouth had painless blister lesions that were relatively improved at the time of admission; she has also complained of dysuria for about two weeks. About one to

two months ago, she first saw a doctor with a headache complaint. A series of tests were requested and medication was prescribed to the patient. According to the patient, the prescribed drugs were neuroleptics, which she refused to take. The patient saw a doctor about two weeks later to introduce the test results. Due to the platelet count of 97000, the tests were requested again for the patient. With the results of both tests in hand, she eventually admitted to an internist on the day before the hospital visit. According to the results of tests with the diagnosis of urinary tract infection, gentamicin, ceftriaxone and normal saline were prescribed for the patient. The patient was advised to drink plenty of fluids, and consequently she consumed large amounts of fruit juices and soft drinks! In experiments dated November 10, 2020, the results for the urine sample showed 7-8 WBCs, many bacteria, and *E. coli*-positive culture. The patient took medications and normal saline with large amounts of juice and soft drinks; but after taking them, her general condition did not change much, and she was restless the night before the visit. Eventually, around the morning, she lost consciousness and returned to the hospital at 10:00 am.

The patient's demographic information and history were collected at the baseline. The caregiver reported No answer for specific disease history, allergies, smoking and surgery in the past. The patient also did not receive any specific medication. The patient was then subjected to a physical examination and she had no symptoms in terms of physical factors, except weakness and lethargy. The patient's weight at the time of referral was 60 kg and the patient's height was 162 cm. The patient had no respiratory distress and was negative for pale and icteric; at the time of admission to the emergency room, the patient had a level of consciousness of GCS = 8, which responded to painful stimuli and was not awake or aware. Foley catheter was placed for the patient, and she was Kussmaul breathing and respiratory distress. Blood pressure at the time of referral was 80:50 mm/Hg, heart rate was 120 beats per minute, respiratory rate was 30 beats per minute and

the patient's body temperature was 36 degrees Celsius. After analyzing the tests performed for the patient, the patient's blood sugar was 2571 mg/dL, BUN was 93 mg/dL and creatinine was 5.6 mg/dL and the patient was suffering from acidosis. The patient's osmolality was 450mosm/kg at the baseline. Other symptoms include high water intake, large volume of urine, blistering lesions of the mouth (from a few days ago), testing with urinary tract infection, tachypnea, tachycardia, and hypotension at the baseline. After analyzing the patient's tests and symptoms, the initial diagnosis was T1D, hyperosmolar hyperglycemic state (HHS) with AKI. After the initial diagnosis, the patient was admitted to the ICU and the patient continued the tests.

After admission, the treatment process began with the use of Insulin therapy IV infusion 6 U/h, Intravenous therapy 350 cc/h,

bicarbonate and antibiotic drugs. As the treatment process continued, the patient's tests were reviewed every few hours. The patient had hypoglycemia during hospitalization (*Figure 1*). The serum osmolality of the patient is also shown in *Figure 2*. As seen in the *Figure 2*, the osmolality trend of the patient's serum was also decreasing. Finally, after 96 hours of hospitalization, she reached a stable condition in terms of physical and after 170 hours normal laboratory examinations. The blood pressure at the time of discharge was 110:70 mm/Hg, heart rate was 80 beats per minute, respiratory rate was 16 beats per minute and body temperature was 36 degrees Celsius. At discharge, the patient's blood sugar was 351 mg/dL, BUN was 51 mg/dL and creatinine was 3 mg/dL, and the patient's osmolality was 290 mosm/kg. Finally, the patient was discharged in normal and stable condition.

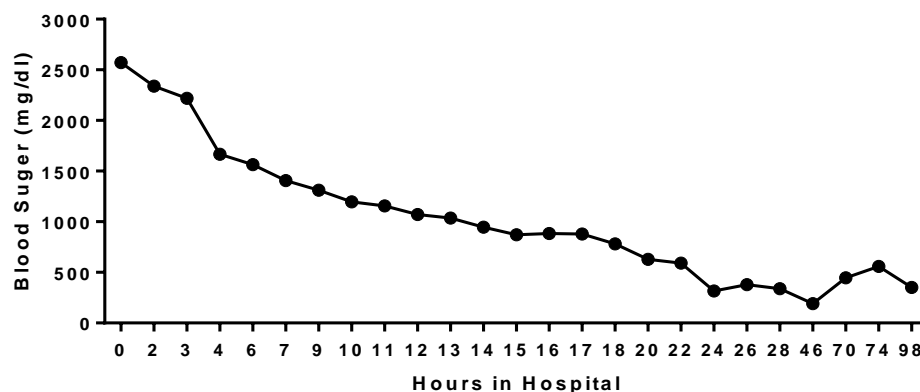


Figure 1. Changes in serum glucose levels during treatment

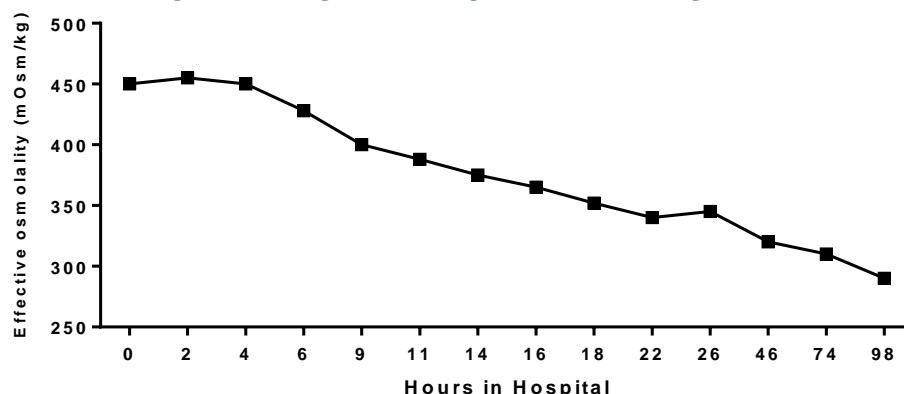


Figure 1. Changes in the effective osmolality level during treatment

Discussion

According to studies to date, HHS and DKA

are among the most important emergencies of hyperglycemia among the complications of T1D. DKA patients show hyperglycemia, which is due to increased production of

hepatic and renal glucose as well as impaired peripheral glucose utilization, eventually causing osmotic diuresis and electrolyte imbalance. Consequences of increased lipolysis and ketoacid production can be ketonemia and metabolic acidosis (9). Apart from DKA, the HHS usually occurs after a long and gradual elevation in polyuria, polydipsia, and consequently severe dehydration, and is associated with doubled loss of fluid in patients with DKA. This in turn causes severe electrolyte loss, which is higher than that observed in DKA due to prolonged osmotic diuresis (7). Hypovolemia occurs due to continued osmotic diuresis, leading to a gradual decrease in glomerular filtration rate (GFR) and worsening of blood sugar (8).

The HHS is rare in T1D patients, which is a rare occurrence with a high mortality rate. The HHS-induced mortality has been reported up to 50-60%. In a cohort study, the 30-day HHS-cause death rate was reported at 16% (10). The HHS mortality rate usually depends on the severity of dehydration, osmolality and age of the patient (8). Blood sugar levels rise as a result of insulin deficiency, increased gluconeogenesis, and the conversion of glycogen to glucose (8). As for hyperglycemia, patients consume large amounts of water, causing electrolyte loss due to urination and subsequent hyperosmolarity. Therefore, osmolality is useful as an indicator of the severity of HHS and for monitoring the rate of change with treatment in the hypersomular state (11). If the osmolality cannot be measured repeatedly, it must be calculated using the formula (12). It is necessary to measure this parameter.

Research has indicated that the HHS is associated with obesity and T2D, but some studies have reported several cases of HHS in T1D and non-obese patients (6, 7, 13). Rosenbloom et al. reported 71 patients with HHS from 2001 to 2008, of whom 49 were obese with HHS and 22 were non-obese. Although T1D was predominant in non-obese survivors, T2D was also present in patients (7).

Hydration therapy should first be on the

agenda for HHS patients. After initial hydration, rapid intravenous insulin should be injected to lower glucose levels and relieve metabolic acidosis. Insulin can prevent the risks of severe hypokalemia and excessive decrease in serum osmolality. Studies demonstrated that strategy therapy may vary with insulin injection rates of 0.1 units per kg/h in patients with DKA and 0.05 units per kg/h in patients with HHS (14, 15).

Acknowledgments

The authors thank the patient for permitting us to report this case.

References

1. Craig ME, Jefferies C, Dabelea D, Balde N, Seth A, Donaghue KC. Definition, epidemiology, and classification of diabetes in children and adolescents. *Pediatric diabetes*. 2014;15(S20):4-17.
2. Kim JH, Lee CG, Lee YA, Yang SW, Shin CH. Increasing incidence of type 1 diabetes among Korean children and adolescents: analysis of data from a nationwide registry in Korea. *Pediatric Diabetes*. 2016;17(7):519-24.
3. Group DP. Incidence and trends of childhood type 1 diabetes worldwide 1990–1999. *Diabetic Medicine*. 2006;23(8):857-66.
4. Levy-Marchal C, Patterson C, Green A. Geographical variation of presentation at diagnosis of type I diabetes in children: the EURODIAB study. *Diabetologia*. 2001;44(3):B75-B80.
5. Wojcik M, Sudacka M, Wasyl B, Ciechanowska M, Nazim J, Stelmach M, et al. Incidence of type 1 diabetes mellitus during 26 years of observation and prevalence of diabetic ketoacidosis in the later years. *European journal of pediatrics*. 2015;174(10):1319-24.
6. Alharfi IM, Singh R, Clarson C, Foster JR. Hyperosmolar hyperglycemic state without ketosis in a toddler with type 1 diabetes. *Pediatric emergency care*. 2014;30(7):485-7.
7. Rosenbloom AL. Hyperglycemic

hyperosmolar state: an emerging pediatric problem. *The Journal of pediatrics*. 2010;156(2):180-4.

8. Pasquel FJ, Umpierrez GE. Hyperosmolar hyperglycemic state: a historic review of the clinical presentation, diagnosis, and treatment. *Diabetes care*. 2014;37(11):3124-31.

9. Siafarikas A, O'Connell S. Type 1 diabetes in children: Emergency management. *Australian family physician*. 2010.

10. Fadini GP, de Kreutzenberg SV, Rigato M, Brocco S, Marchesan M, Tiengo A, et al. Characteristics and outcomes of the hyperglycemic hyperosmolar non-ketotic syndrome in a cohort of 51 consecutive cases at a single center. *Diabetes research and clinical practice*. 2011;94(2):172-9.

11. Scott A. The management of the hyperosmolar hyperglycaemic state in adults with diabetes: a summary of a report from the Joint British Diabetes Societies for Inpatient Care. *British Journal of Diabetes*. 2015;15(2):89-93.

12. Chiasson J-L, Aris-Jilwan N, Bélanger R, Bertrand S, Beaugard H, Ékoé J-M, et al. Diagnosis and treatment of diabetic ketoacidosis and the hyperglycemic hyperosmolar state. *Cmaj*. 2003;168(7):859-66.

13. Hernández Moreno A, Sanz Fernández M, Ballesteros Pomar MD, Rodríguez Sánchez A. Hiperglycemic hyperosmolar state: An unusual way of first appearance of type 1 diabetes in children. 2016.

14. Arora R, Chiwane S, Hartwig E, Kannikeswaran N. A child with altered sensorium, hyperglycemia, and elevated troponins. *The Journal of emergency medicine*. 2014;46(2):184-90.

15. Cho YM, Park BS, Kang MJ. A case report of hyperosmolar hyperglycemic state in a 7-year-old child: An unusual presentation of first appearance of type 1 diabetes mellitus. *Medicine*. 2017;96(25).