



Unusual Presentation of Breast Metastasis Mimicking Skin Abscess

Armaghan Kazeminejad¹, Mohammad Jafar Ghahari², Ali Mirabi³, Lotfollah Davoodi^{4*}, Mohammad Tabarestani³

¹ Assistant Professor of Dermatology, Mazandaran University of Medical Sciences, Sari

² Medical Doctor, Department of Health, Mazandaran University of Medical Science, Sari.

³ Medical Student, Student Research Committee, Mazandaran University of Medical Sciences, Sari, Iran.

⁴ Assistant Professor, Infectious Disease Research Center, Mazandaran University of Medical Science, Sari, Iran.

The primary malignant tumor that most commonly metastasizes to the skin in women is breast cancer and manifest variety forms of clinical presentation. Breast cancer has the ability to metastasize to any site such as the ovaries, lung, liver, bone, brain, gastrointestinal tract and skin. The skin is not a common site for metastatic spread. We would like to report a case of a 56 years old female patient with an infectious mass in her left inframammary fold with discharge. The patients had a one-year history of left breast pruritus and with a mass which increased in size over two months. There was axillary lymphadenopathy, tenderness, and erythema of breast skin around the mass in the physical examination and just elevated erythrocyte sedimentation rate in laboratory tests. The patient did not benefit from antimicrobial therapy. The histological examination revealed a tumor with sheets of malignant cells and many necrotic areas. The diagnosis was invasive ductal breast carcinoma, cutaneous metastases, and lymphatic embolization.

Keywords: Invasive Ductal Carcinoma, Breast Cancer, Skin Metastasis

How to cite this article: Kazeminejad A, Ghahari MJ, Mirabi A, Davoodi L, Tabarestani M. Unusual Presentation of Breast Metastasis Mimicking Skin Abscess. *Tabari Biomed Stu Res J.* 2019;1(4):25-27DOI: 10.18502/tbsrj.v1i4.2252.

Introduction

Breast cancer is the most frequently diagnosed cancer in women and the second leading cause of cancer death in women [1, 2]. Breast cancer has the ability to metastasize to any site such as the ovaries, lung, liver, bone, brain, gastrointestinal tract and skin [3]. The skin is not a particularly common site for metastatic spread, therefore when the skin is affected by metastases, it considered as a sign of poor prognosis [4]. Of all the carcinomas that can metastasize to the skin, breast cancer is the most frequent cause of skin metastases, so that it is responsible for 24% of skin metastases in women [5, 6]. Among the histological subtypes of breast cancer, metastases of invasive ductal carcinoma are rare. Carcinomatous cells spread through interstitial space, bloodstream or lymphatic vessels [4]. Accordingly, it has various presentation such as vascular-appearing papules, papulonodules, patches of erythema mimicking erysipelas and cellulitis

(inflammatory breast carcinoma) sclerodemoid and morpheaform [7]. We report a female with an exophytic mass in her left inframammary fold and discharge mimicking an infectious mass from 2 months.

Case presentation

A 56-year-old woman was referred to with an 8-weeks history of an exophytic mass in her left inframammary fold and discharge (Figure 1). She had a one-year history of left breast pruritus and said that the mass was increased in size over two months. There was also gradual weight loss in the previous year. In physical examination axillary lymphadenopathy, tenderness and erythema of breast skin around the mass were seen. She denied any dermatological diseases and her personal history was unremarkable. Elevated erythrocyte sedimentation rate (ESR) was seen in her lab tests. Other lab data was normal. The patient underwent antibiotic therapy without significant response.

* Corresponding author: **Lotfollah Davoodi**, Assistant Professor, Infectious Disease Research Center, Mazandaran University Of Medical Science, Sari, Iran. Email: Lotfdavoodi@Yahoo.Com.

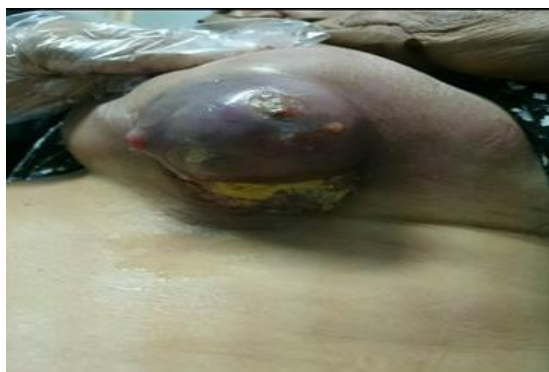

Figure 1; cutaneous metastasis of breast carcinoma in a 56-year-old woman

The histological examination revealed that the tumor was composed of sheets of malignant cells and many necrotic areas. The neoplastic cells have large pleomorphic vesicular nuclei some with prominent nucleoli and mitotic figure. The diagnosis was invasive ductal breast carcinoma, cutaneous metastases and lymphatic embolization (Figure 2). Then the patient underwent a computed tomography scan. Computed tomography revealed a sizeable contrast-enhanced tumor in the left breast and infiltration of the left lung.

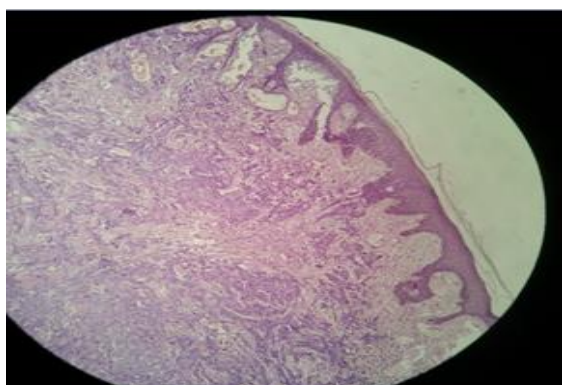


Figure 2; histopathological view of cutaneous metastasis of breast carcinoma, discrete islands of tumor cells within the dermis.

Discussion

Breast carcinoma is the most common malignant tumor that metastasizes to the skin [1,2]. Cutaneous breast cancer metastasis can be expressed with variable morphology such as papulonodular lesions, inflammatory breast carcinoma, scleroderma infiltration (carcinoma en cuirasse), carcinoma telangiectaticum, zosteriform and alopecia neoplastica [7]. But based on our literature search, there has been a few reports of breast carcinoma presenting as a breast abscess or infectious mass.

Our case presented with a breast tumor resembling an infectious mass. Inflammatory breast

carcinoma clinically resembles a benign bacterial infection of the breast such as erysipelas, cellulitis or abscess. This benign appearance can lead to delay in diagnosis and treatment [8, 9]. This presentation of breast cancer is very rare. When a patient refers to us with inflammatory lesion without any sign of fever and leukocytosis and when antibiotic use results in no improvement of lesions, we should consider the inflammatory breast carcinoma. A biopsy for histopathologic evaluation can help us to roll out the metastatic process. A usual ductal adenocarcinoma was not identified even with extensive sampling. These tumors usually have rapidly growing pattern enlarging over a period of 2–3 weeks. Approximately two-thirds of them are also cystic or have a cystic component with central necrosis [10]. It was an important problem that rapidly progressed cystic or infectious mass lesions can be the malignant presentation. Nodal metastases are relatively uncommon, so the roles of sentinel lymph node mapping or axillary dissection are unclear; our case has demonstrated metastatic involvement of an axillary lymph node in physical examination [11].

Highest incidence of cutaneous metastases ranges between 50 and 70 years old. Usually, the metastasis occurs first 3 years from the primary tumor diagnosis [12, 13]. The classification of inflammatory breast disorders according to etiology was discussed in a paper by Kamal et al. [14] in their study; the cases of mastitis were categorized into three types: infectious, noninfectious and malignant, with the latter comprising 5.6% of mastitis cases and accompanying inflammatory breast carcinoma, or very rarely, malignant breast abscess. Kamal et al recognized that ultrasonographic features could scarcely differentiate between infectious and malignant cases. Ill-defined collections and abscess cavities were in favor of the infectious type, while malignant axillary nodes were in favor of the malignant type. The authors recommended that non-lactating women with antibiotic-resistant cases of mastitis undergo immediate mammography, ultrasonography, skin biopsy and aspiration of the subdermal lymphangitis to exclude cancer [14].

In our patient, the first presentation of breast cancer was inframammary dermatitis. Our patient mistreats herself several months as inframammary dermatitis with topical steroid. Lack of awareness about her breast cancer leads to delay in diagnosis. Prognosis of patients with metastatic skin lesions depends on the type and biological behavior of the tumor. This carcinoma with skin metastasis is associated with advanced cancer and prognosis is reserved and therapy often ineffective.

We reported a rare case of the breast cancer presenting as a breast abscess that slowly

progressed. This case illustrates that an apparently benign infectious disorder such as a breast abscess might occasionally be related to a clinically occult malignancy. Complicated cysts and breast abscesses should always be evaluated through histopathological examination.

Conclusion

In summary, infectious mass in the breast is a rare form of breast cancer presentation, therefore when a patient refers to us with infectious mass without other sign of inflammation, we must consider inflammatory breast carcinoma as differential diagnosis and primary responsibility of the dermatologist.

Disclosure

Authors declare no conflict of interest.

Acknowledgment

We would like to thank the colleagues of Antimicrobial Resistance Research Center in Razi Hospital.

Conflicts of interest

None.

References

1. Siegel R, Ma J, Zou Z, Jemal A. Cancer statistics, 2014. *CA: a cancer journal for clinicians*. 2014;64(1):9-29.
2. Krathen RA, Orengo IF, Rosen T. Cutaneous metastasis: a meta-analysis of data. *Southern medical journal*. 2003;96(2):164-168.
3. Cummings MC, Simpson PT, Reid LE, Jayanthan J, Skerman J, Song S, et al. Metastatic progression of breast cancer: insights from 50 years of autopsies. *The Journal of pathology*. 2014;232(1):23-31.
4. Sittart JAdS, Senise M. Cutaneous metastasis from internal carcinomas: a review of 45 years. *Anais brasileiros de dermatologia*. 2013;88(4):541-544.
5. Lookingbill DP, Spangler N, Helm KF. Cutaneous metastases in patients with metastatic carcinoma: a retrospective study of 4020 patients. *Journal of the American Academy of Dermatology*. 1993;29(2):228-236.
6. Alcaraz I, Cerroni L, Rütten A, Kutzner H, Requena L. Cutaneous metastases from internal malignancies: a clinicopathologic and immunohistochemical review. *The American journal of dermatopathology*. 2012;34(4):347-393.
7. De Giorgi V, Grazzini M, Alfaioli B, Savarese I, Corciova SA, Guerriero G, Lotti T. Cutaneous manifestations of breast carcinoma. *Dermatologic therapy*. 2010;23(6):581-589.
8. Yaghoobi R, Talaizade A, Lal K, Ranjbari N, Sohrabiaan N, Feily A. Inflammatory Breast Carcinoma Presenting with Two Different Patterns of Cutaneous Metastases: Carcinoma Telangiectaticum and Carcinoma Erysipeloides. *The Journal of clinical and aesthetic dermatology*. 2015;8(8):47-51.
9. Yamauchi H, Woodward WA, Valero V, Alvarez RH, Lucci A, Buchholz TA, Iwamoto T, Krishnamurthy S, Yang W, Reuben JM, Hortobágyi GN, Ueno NT. Inflammatory breast cancer: what we know and what we need to learn. *The oncologist*. 2012;17(7):891-899.
10. Shigekawa T, Tsuda H, Sato K, Ueda S, Asakawa H, Shigenaga R, Hiraide H, Mochizuki H. Squamous cell carcinoma of the breast in the form of an intracystic tumor. *Breast cancer*. 2007;14(1):109-112.
11. Gupta C, Malani AK, Weigand RT, Rangineni G. Pure primary squamous cell carcinoma of the breast: a rare presentation and clinicopathologic comparison with usual ductal carcinoma of the breast. *Pathology-Research and Practice*. 2006;202(6):465-469.
12. Sun SKHCZ, Pang QPRMH. Cutaneous metastasis of breast cancer previously diagnosed 25 years ago. 2014;127(5):p1000.
13. Oliveira GMd, Zchetti DBC, Barros HR, Tiengo A, Romiti N. Breast carcinoma en Cuirasse-case report. *Anais brasileiros de dermatologia*. 2013;88(4):608-610.
14. Kamal RM, Hamed ST, Salem DS. Classification of inflammatory breast disorders and step by step diagnosis. *The breast journal*. 2009;15(4):367-380.